

Case Reports

Spontaneous rupture of malarial spleen presenting as hemoperitoneum: a case report

Nikhil Gupta, Pawanindra Lal, Anubhav Vindal, Niladhar S. Hadke & Nita Khurana

Maulana Azad Medical College, New Delhi, India

Key words Hemoperitoneum; malaria; *Plasmodium*; spleen

Malaria has been among the most common infectious diseases in India. The causative microorganism belongs to the *Plasmodium* family. The four common species that are encountered are *Plasmodium falciparum*, *P. vivax*, *P. malariae* and *P. ovale*. *Plasmodium falciparum* infection carries more risk of complications such as cerebral malaria, acute renal failure, liver damage, collapse etc. *Plasmodium vivax* is considered to be benign but splenic complications are more common with *P. vivax* infections¹. Spontaneous rupture of malarial spleen is uncommon even in the endemic regions of malaria. This may lead to delayed or missed diagnosis of splenic rupture which may be life threatening². Very few case reports are available in literature documenting spontaneous rupture of malarial spleen^{1–6}. We are reporting one such instance of malarial splenic rupture encountered in our department.

Case report: A 24-yr old male came to surgical emergency in September 2009 with history of fever with chills for five days and abdominal pain with distension for one day. There was no history of any trauma or abnormal bleeding. The patient's extremities were cold and his pulse rate was 124/min. He was pale and his abdomen was distended with tenderness over left hypochondrium. The hemoglobin level was 5.4 g% and peripheral smear showed *P. vivax* species. Sonography of the abdomen revealed laceration in the inferior pole of spleen with free fluid in

the abdomen. All the other investigations were within normal range. Patient was taken for urgent laparotomy after transfusing four units of whole blood. Intraoperatively, spleen was found to be enlarged, friable with lacerated inferior pole and multiple bleeding points. Splenectomy was carried out and patient received antimalarial therapy in post-operative period. Histopathology of the specimen showed malarial pigments in macrophages thus confirming the diagnosis of malarial spleen (Fig. 1).

In India, approximately 55% of the cases are caused by *P. vivax* whereas in 40–42% of the cases, culprit is *P. falciparum* which is notorious for giving rise to complications^{1,2,7–9}. As a result, splenic rupture may be missed or diagnosed late. Spleen involvement is very common in malaria approaching 50–70% in endemic areas. It is normally palpable on 3rd to 4th

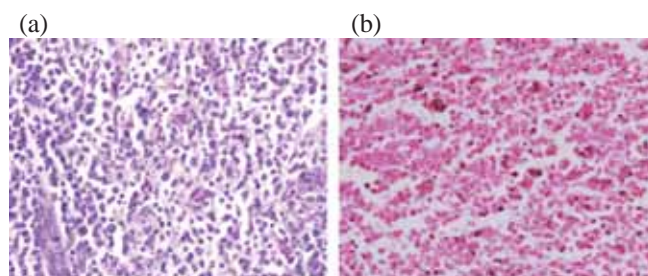


Fig. 1: (a) Splenic macrophages with granular fine brown black pigment [H&E ×400]; and (b) Black pigment in the macrophages negative with Perl's stain ×400.

day of the onset of symptoms. Non-traumatic rupture of malarial spleen is a rare phenomenon because malarial spleen is tougher as compared to normal spleen. It is mostly seen in acute phase and that too in primary attack. In most of the cases, the first event is subcapsular hematoma. Minor or un noticed pressure due to vomiting, bending or coughing in addition to splenic congestion, infarction and focal necrosis leads to distension of the splenic capsule and rupture.

Other diseases giving rise to non-traumatic rupture of spleen are infectious mononucleosis, neoplasms and haematological malignancies. Orloff and Peskin¹⁰ had suggested few criteria for labelling any case as spontaneous rupture of spleen: (i) no history of trauma; (ii) absence of any disease affecting spleen directly or indirectly; (iii) absence of perisplenic adhesions or scarring; and (iv) presence of normal spleen, macroscopically and microscopically. Splenic complications must be sought by a physician in any patient of malaria who presents with nausea, vomiting, abdominal pain or distension. Splenic hematoma should be monitored by repeated USG to assess its progress. Splenic rupture with hemoperitoneum should be managed with laparotomy and splenectomy along with antimalarial drugs. High index of suspicion is needed to detect these complications early.

Corresponding author: Dr Nikhil Gupta, Department of Surgery, Maulana Azad Medical College, New Delhi-110 002, India.
E-mail: nikhil_ms26@yahoo.co.in

Received: 14 January 2010

Accepted in revised form: 12 March 2010

References

1. Ozsoy MF, Oncul O, Pekkafali Z, Pahsa A, Yenen OS. Splenic complications in malaria: report of two cases from Turkey. *J Med Microbiol* 2004; 53: 1255–8.
2. Choudhury J, Uttam KG, Mukhopadhyay M. Spontaneous rupture of malarial spleen. *Indian Pediatr* 2008; 45: 327–8.
3. Yagmur Y, Kara IH, Aldemir M, Büyükbayram H, Tacyildiz IH, Keles C. Spontaneous rupture of malarial spleen: two case reports and review of literature. *Crit Care* 2000; 4: 309–13.
4. Abouzahir A, Bouchama R. Spontaneous spleen rupture in the course of malaria. *Med Mal Infect* 2008; 38: 153–5.
5. Hamel CT, Blum J, Harder F, Kocher T. Non-operative treatment of splenic rupture in malaria tropica: review of literature and case report. *Acta Trop* 2002; 82(1): 1–5.
6. Tauro LF, Maroli R, D'Souza CR, Hegde BR, Shetty SR, Shenoy D. Spontaneous rupture of the malarial spleen. *Saudi J Gastroenterol* 2007; 13: 163–7.
7. Dash AP, Valecha N, Anvikar AR, Kumar A. Malaria in India: challenges and opportunities. *J Biosci* 2008; 33: 583–92.
8. Sharma VP. Current scenario of malaria in India. *Parassitologia* 1999; 41(1-3): 349–53.
9. Kumar A, Valecha N, Jain T, Dash AP. Burden of malaria in India: retrospective and prospective view. *Am J Trop Med Hyg* 2007; 77(6 Suppl): 69–78.
10. Orloff MJ, Peskin GW. Spontaneous rupture of the normal spleen, a surgical enigma. *Surg Gynaecol Obstet* 1958; 106: 1–11.